

Dysmorphic Pelves Treatment with the CurvaFix® IM System

James Shaw, MD | McGovern Medical School, Houston, Texas

CASE PRESENTATION

Patient 1 is a 59-year-old male who fell 20 feet from scaffolding and sustained subdural hemorrhage, multiple rib fractures, an open left humerus fracture, and pelvic ring injury.

Patient 2 is a 32-year-old female pedestrian struck by an automobile and sustained grade II liver lacerations, multiple rib fractures, a right clavicle fracture, and pelvic ring injury.

DIAGNOSIS

Patient 1 sustained a complete right sacral fracture with traversing fracture lines and a right iliac crescent fracture.

Patient 2 sustained a right zone 2 sacral fracture, right parasymphyseal superior ramus fracture and inferior ramus fracture. Patient 2 had more acute sacral dysmorphism than patient 1.

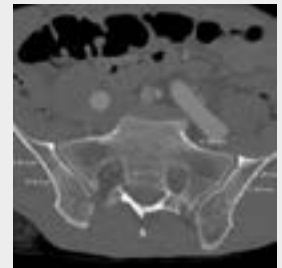CURVAFIX IM IMPLANTS

- CurvaFix IM Implants were inserted into the upper sacral segments of both patients.
- Patient 1 received both a straight screw in S2 and a CurvaFix implant in S1. Both wires were placed prior to the implantation of the CurvaFix implant so visibility could be maintained.

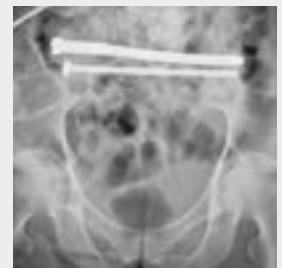FOLLOW-UP

Patient 1 was lost to follow up.

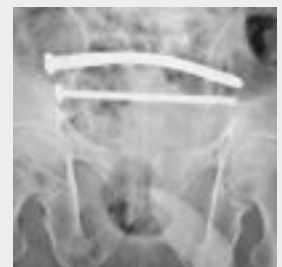Patient 2 was fully weight bearing at 10 weeks with minimal pain in the pelvis.



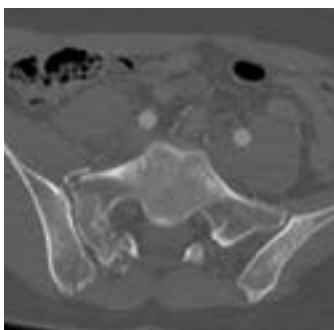
Patient 1: Preoperative CT



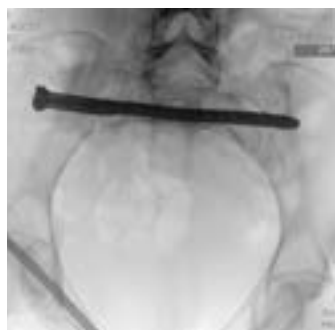Patient 1: Postoperative



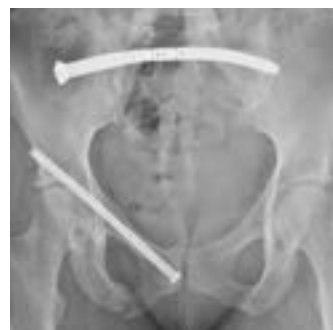Patient 1: Postoperative



Patient 2: Preoperative CT



Patient 2: Postoperative



Patient 2: 10-week follow-up

KEY POINTS

- The steerable guidewire and CurvaFix IM Implant accommodate the curved intraosseous anatomy in patients with pelvic dysmorphism to obtain transiliac-transsacral fixation in the upper sacral segments.
- CurvaFix allowed for transiliac-transsacral fixation that would otherwise not be possible with traditional straight screws.
- Passing wires into both S1 and S2 (patient 1) prior to the CurvaFix IM Implant insertion preserved visibility during the second wire insertion for the straight screw.